Osteopathic treatment in a child subject affected by ischemic hypoxic encephalopaty

Case Report

Authors

Manuela Di Vito

Osteopath

D.O. m R.O.I.

Federica Di Bacco

Osteopath

D.O. m R.O.I.

Angelo Luca Del Vecchio

Medical Degree

Osteopath

D.O. m R.O.I.

Marcello Luca Marasco

Fisioterapist

Osteopath

D.O. m R.O.I.

Our pediatric clinic

In AbeOS osteopathy school from 2015, children of all ages are welcomed, and osteopathic support is guaranteed

The head of the pediatric clinic is Gabriella Colangelo, a founding member of the San Marino pediatric osteopathy foundation

In four years we have evaluated 150 kids, from tutors and students of the AbeOS school, with significant clinical success

What is ipoxic- hyschemic encefalophaty?

Is a neurological disorder that affects the natal or perinatal age.

The estimated incidence is about 1-2/1000 born at term. The 60% in the premature infants.

The Higher Institute of Health claims to be the major cause of infant death

This condition causes damage of different nature based on the gestational age

Factor risks -1

Before pregnancy

Like delay of mother, hyperthyroidism, maternal convulsive syndrome

During the first half pregnancy

Like proteinuria >5g \ 25, Metrorrhagia

During labor

Fetal bradycardia, placenta previa, infections of chorion

Factors risks -2

At the birth

- Low neonatal weight
- First breath after 5 minutes
- APGAR index greater or equal to six
- Microcephaly reflex
- Congenital malformations of nervous system

What are the consequences of hypoxic hischemic encefalophaty ?

Neurological disorder

Like cerebral palsy, Mental retardarion, learning disabilities, epilepsy

Damage of tissue

Like damage on cortex, hippocampus, basal ganglia, thalamus and grey matter

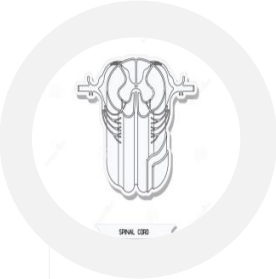

Vulnerability of white matter

In periventricular regions white matter result more vulnerable

Focal brain lesions

Like poor developement of language and cognitive skills

Case report

Matherial and methods -1

The subject was a 4 year-old girl affected by double spastic hemiplegia with impared motor symmetry.

She was born with natural birth at 34 weeks gestational age with a weight of 2,350kg and absence of first breath.

At the observation emerges that the use of the upper limbs corresponds to a stiffening of the lower limbs. The subject wore tutors at lower limbs.

Matherials and methods - 2

MRI

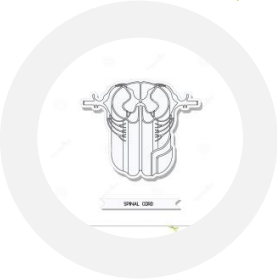

Volumetric reduction of the white substance and an expansion of the lateral ventricles

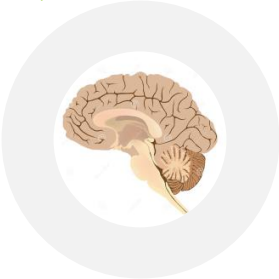

Thinning of the corpus callosum

Positive and greater left Babinsky reflex with very reduced left foot dorsiflexion

Matherial and methods - 3

The child was evaluated and treated with OMT for five sessions every two months.

OMT focused on the articular mobility of the pelvis and feet and the cardio-circulatory system.

Emerged disfunction on occipital condyles and C1 probably related to hypoxia.

Results

During the treatments emerged a gradual improvement of the posture, also noticed by other health professionals who deal with the case

The dorsiflexion has had a marked improvement, concomitant with a general release of the musculature

Now the patient reduces the use of lower limbs orthotics and she can walk without it

Discussion

Ischemic Hypoxic encephalopathy is a condition that involves the nervous system. It can be deadly or, in case of survival of the subject, it is cause of neurological disability. In the reported case it was observed that the subject has had considerable and evident improvements regarding the motor and muscle component, probably correlated to the young age of the same and to the probable slight entity of hypoxia.

Conclusions

- OMT combined with traditional pharmacological and health care (such as physiotherapy, speech therapy, etc.) can be efficient for the purpose of motor recovery of the subject
- OMT makes the tissue more elastic by increasing the dorsiflexion of the foot and reducing the presence of the Babinski reflex
- OMT can act on the neuroplasticity which is the capacity of the immature nervous tissue to recondition.

Thanks for your attention!